

Medscape Reference
Reference

- [News](#)
- [Reference](#)
- [Education](#)
- [MEDLINE](#)



Mandibular Nerve Block

- Author: Anusha Cherian, MBBS, MD, DNB; Chief Editor: Meda Raghavendra (Raghu), MD [more...](#)

Updated: Jan 27, 2012

Background

Mandibular nerve block involves blockage of the auriculotemporal, inferior alveolar, buccal, mental, incisive, mylohyoid, and lingual nerves. It results in anesthesia of the following areas:

- Ipsilateral mandibular teeth up to the midline
- Buccal and lingual hard and soft tissue on the side of the block
- Anterior two-thirds of the tongue
- Floor of the mouth
- Skin over the jaw, the posterior part of the cheek, and the temporal area

Mandibular nerve block is a safe procedure. The process of obtaining informed consent should include discussion of the risk of temporary numbness and paresthesia in the involved region.

Indications

The mandibular nerve area is generally blocked by using more specific nerve blocks rather than by performing a complete nerve block. Indications for complete nerve block include the following:

- Patients in whom the inferior alveolar nerve (IAN) block fails or is not feasible – Sometimes the teeth may be innervated by an accessory nerve that arises proximal to the IAN and thus may be spared by an IAN block
- Patients undergoing surgical procedures of the mandible – Mandibular nerve block may be done either as an isolated nerve block or as a complement to general anesthesia; this is applicable to several dental procedures on the lower teeth and surrounding soft tissues

The mandibular nerve block has a success rate of 95%-98%, whereas the IAN block is successful in only 65%-85% of cases.

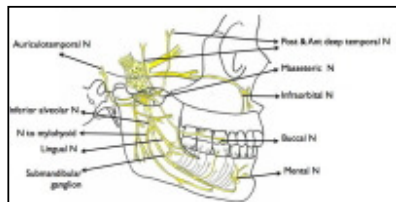
Contraindications

Contraindications for mandibular nerve block include the following:

- Acute inflammation at the site of injection
- Trisomatic patients, uncooperative patients, and children (these are specific to the Gow-Gates block [see Technique])
- Acute infection in the pterygomandibular space, fracture of the mandible, presence of a tumor, or distortion of the regional anatomy (these are specific to the Vazirani-Akinosi block [see Technique])
- Patients with known allergies to local anesthetic

Technical Considerations

The mandibular nerve is the largest division of the trigeminal nerve, with sensory roots from the trigeminal ganglion and motor roots from the pons and the medulla. The 2 roots exit the cranium via the foramen ovale and unite just outside the cranium to form the mandibular nerve. After giving off 2 branches, the mandibular nerve bifurcates into anterior and posterior divisions (see the image below).



Branches of the mandibular nerve

From the main trunk, the nervus spinosus reenters the cranium via the foramen spinosum to provide sensory innervation to the meninges. The nerve to the medial pterygoid is a motor branch that innervates the medial pterygoid muscle. It divides into 2 branches, which are the nerves to the tensor tympani and the tensor veli palatini.

Motor nerves from the anterior division include the following:

- Masseteric nerve, which supplies the masseters
- Temporal nerve, which serves the temporalis
- Lateral pterygoid nerve, which supplies the lateral pterygoid muscle

Sensory nerves from the anterior division include the buccal nerve, which is sensory to the mucosa of the mouth and gums and the skin on the cheek.

Sensory nerves from the posterior division include the following:

- Auriculotemporal nerve, which is sensory to the external auditory meatus and the external surface of the tympanic membrane
- Lingual nerve, which travels inferiorly into the pterygomandibular space between the mandibular ramus laterally and the medial pterygoid muscle medially; this nerve provides general sensation to the anterior two-thirds of the tongue, the floor of the mouth, and the lingual gingiva

The IAN descends into the pterygomandibular space along with the lingual nerve. Its sensory branch enters the mandibular canal and is sensory to the lower teeth and gums. It then exits via the mental foramen as the mental and incisive nerves, which are sensory to the chin and the lower teeth. The motor branch to the mylohyoid is given off before the nerve enters the mandibular canal and serves as motor supply to the mylohyoid muscle.

Contributor Information and Disclosures

Author

Anusha Cherian, MBBS, MD, DNB Assistant Professor, Department of Anesthesiology and Critical Care, Jawaharlal Institute of Postgraduate Medical Education and Research, India

Disclosure: Nothing to disclose.

Coauthor(s)

Nanda Kishore Maroju, MBBS, MS, DNB, MRCS Assistant Professor of Surgery, Jawaharlal Institute of Postgraduate Medical Education and Research, India

Nanda Kishore Maroju, MBBS, MS, DNB, MRCS is a member of the following medical societies: [Royal College of Surgeons of Edinburgh](#)

Disclosure: Nothing to disclose.

Chief Editor

Meda Raghavendra (Raghu), MD Associate Professor, Interventional Pain Management, Department of Anesthesiology, Chicago Stritch School of Medicine, Loyola University Medical Center

Meda Raghavendra (Raghu), MD is a member of the following medical societies: [American Association of Physicians of Indian Origin](#), [American Society of Anesthesiologists](#), and [American Society of Regional Anesthesia and Pain Medicine](#)

Disclosure: Nothing to disclose.

References

1. Sisk AL. Evaluation of the Akinosi mandibular block technique in oral surgery. *J Oral Maxillofac Surg*. Feb 1986;44(2):113-5. [[Medline](#)].
2. Budenz AW, Osterman SR. A review of mandibular anesthesia nerve block techniques. *J Calif Dent Assoc*. Sep 1995;23(9):27-34. [[Medline](#)].
3. Gaum LI, Moon AC. The "ART" mandibular nerve block: a new approach to accomplishing regional anesthesia. *J Can Dent Assoc*. Jun 1997;63(6):454-9. [[Medline](#)].
4. Haas DA. Alternative mandibular nerve block techniques: a review of the Gow-Gates and Akinosi-Vazirani closed-mouth mandibular nerve block techniques. *J Am Dent Assoc*. Sep 2011;142 Suppl 3:8S-12S. [[Medline](#)].
5. Sisk AL. Evaluation of the Gow-Gates mandibular block for oral surgery. *Anesth Prog*. Jul-Aug 1985;32(4):143-6. [[Medline](#)]. [[Full Text](#)].
6. Gow-Gates G, Watson JE. Gow-Gates mandibular block--applied anatomy and histology. *Anesth Prog*. Jul-Oct 1989;36(4-5):193-5. [[Medline](#)].
7. Kafalias MC, Gow-Gates GA, Saliba GJ. The Gow-Gates technique for mandibular block anesthesia. A discussion and a mathematical analysis. *Anesth Prog*. Jul-Aug 1987;34(4):142-9. [[Medline](#)]. [[Full Text](#)].

Medscape Reference © 2011 WebMD, LLC